

Tactics of surgical treatment in necrotising enterocolitis stage II-B in newborn

Alisher Vakhidov^{1*}, *Dilfuzahon Mamarasulova*¹, and *Akmal Khaitov*¹

¹Termez branch of the Tashkent Medical Academy, Surkhandarya region, Islam Karimov street, 64, 132000, Termez, Uzbekistan

Abstract. An analysis was made of the results of surgical treatment of 18 newborns with a diagnosis of stage II-B NEC, admitted in the period from 2018 to 2022. The aim of the work: to analyze the results of surgical treatment for stage II-B necrotizing enterocolitis in newborns using modern technologies. A total of 18 diagnostic laparoscopies (DL) were performed, of which 4 cases were converted - laparotomy. In 14 patients cases, DL was completed by therapeutic laparoscopy using minilaparotomy with video-assessment, including 8 patients, resection of the necrotic portion of the intestine was performed with end-to-end anastomosis. In 6 cases, an intestinal stoma was applied through a minilaparotomy. In comparison, after laparoscopic operations with video assessment, mortality was observed of cases 1 patient out of 14, after traditional surgical interventions, mortality was in 25% of cases 1 patient out of 4. Based on the results of DL at the surgical stage of NEC, it is possible to build further tactics of radical surgical treatment, the possibility of transforming it into a therapeutic one minimizes intraoperative trauma, which positively affects the postoperative survival of patients.

1 Introduction

The incidence of NEC in newborns, according to various authors, ranges from 0.3 to 3 per 1000 children. Given the nonspecificity and polymorphism of NEC signs in the early stages of the disease, it is both easy and difficult to suspect this pathology at the same time [1, 2]. In the neonatal period, NEC occurs in 2-16% of cases, depending on gestational age, about 80% of them occur in preterm infants with low birth weight. In term infants, NEC occurs in 10–25% of cases [3, 4]. The condition of patients with NEC who are under intensive treatment in the intensive care unit is so severe that it is not always possible to notice signs of an impending catastrophe from the gastrointestinal tract in time [5, 6]. The mortality rate is much higher in the group of premature newborns, among children with intrauterine growth retardation syndrome and ranges from 28 to 54%, and after surgical interventions - 60-75%, despite the intensive joint efforts of neonatologists, pediatric surgeons, anesthesiologists-resuscitators, as well as the development of modern technologies for nursing and treatment of newborns. The vast majority of these children (90%) are preterm with a body weight of less than 1500 g, which is why NEC is called the "survivor of prematurity disease". Peritonitis

* Corresponding author: Doc_vash@mail.ru

is the most common (86.5%) complication [7,8]. In treatment, if laparotomy is chosen, the surgical procedure includes options for resection with or without anastomosis, creation of an external intestinal stoma, and the use of the clip-and-dip technique. According to most authors, the operation of choice is resection of the necrotic portion of the intestine with the removal of a double intestinal stoma, and in case of total damage to the colon, it is switched off by imposing an unnatural anus on the ileum [9,10].

2 Material and research methods

We analyzed the results of treatment of 18 newborns (11-61.1% boys, 7-38.9% girls) diagnosed with stage II-B NEC admitted to the neonatal surgery department of our center for the period from 2018 to 2022. In most cases, the reason for the transfer of newborns to our clinic was a sharp deterioration in the condition of children: regurgitation and vomiting of stagnant contents, often "coffee grounds", severe swelling, local pastosity, tension and soreness of the abdomen, expansion of the subcutaneous venous network of the anterior abdominal wall. In some cases, skin hyperemia and swelling in the lower abdomen and genitals, scanty stools with or without blood, pronounced hemodynamic disturbances - centralization of blood circulation, dehydration, infectious toxicosis were observed. The age of the children varied from the first hours of life to 14 days. For the first time on the 3rd day of life with a clinical picture of NEC, 4 (22.2%) newborns were admitted, 11 (61.1%) on the 5-10th day of life, 3 (16.7%) were admitted at a later date.

In 66.7% of observations (12 children), the children were premature, the average gestational age, which was from 26 to 37 weeks (mainly 32-36 weeks). Delivery by caesarean section was in 3 (16.6%) women. From the history of intrauterine hypoxia and asphyxia, 16 (88.8%) children suffered, intrauterine infection - 15 (83.3%). 14 (77.7%) newborns had perinatal CNS damage, 5.5% (1) had critically low body weight (less than 1000 g). At birth, 3 (16.7%) children underwent resuscitation measures: indirect heart massage, sanitation of the upper respiratory tract, tracheal intubation and mechanical ventilation.

At admission, along with clinical and biochemical blood tests, all children underwent ultrasound examination (ultrasound) and plain radiography of the abdominal organs (ABP).

According to the results of clinical and biochemical blood tests of patients, acidosis of varying severity was established, leukopenia in (4 children) 22.2%, thrombocytopenia in (10 children) -55.6%, signs of DIC (8 children) 44.4%, sepsis 66.7% (12 children) and oligoanuria in 44.4% (8 children) cases.

3 Results and discussions

Like most researchers in this work, we used the working classification of M. Bell in the modification of M. Walsh and Kliegman (1987), which allows not only timely diagnosis of NEC, but also to determine the stage of development of the disease, according to which we chose treatment tactics. As is known, the prognosis of NEC treatment largely depends on the surgical stage of the disease, the severity of symptoms and consists of preoperative preparation, surgical tactics, competing diseases and complications of the underlying disease against the background of prematurity and immaturity of the patient's body as a whole.

Upon admission to our center, all newborns with stage II-B NEC were hospitalized in the intensive care unit (ICU), where they underwent intensive preoperative preparation.

Preoperative preparation included: decompression of the stomach and large intestine using probes, selection of adequate parameters of lung ventilation to ensure normal gas exchange, correction of hemodynamic disturbances, stabilization of blood pressure, correction of electrolyte disturbances, acid-base status, hypovolemia, restoration or

maintenance of diuresis at a level of at least 1.5 - 2.0 ml / kg / hour, hemo- and plasma transfusion (according to indications), intravenous administration of broad-spectrum antibiotics.

The criteria for stabilization of the patient's condition were; - restoration of diuresis, the appearance of a pulse in the peripheral arteries, improvement in blood pressure, saturation (SpO₂ not less than 90-94%). The duration of preoperative preparation ranged from 3 to 6 hours from the moment the child was admitted to the hospital (average 4.5 ± 0.5 hours).

One of the main radiological indications for surgical treatment in stage II-B NEC was the expansion of intestinal loops with multiple horizontal levels, pneumatosis, thickening of the intestinal wall, gas in the portal system of the liver, ascites. In all cases of stage II-B NEC, surgical treatment was preceded by DL, based on the results of which further surgical tactics were built, but it was not successful in all cases, in 4 (22.2%) cases conversion was performed due to technical difficulties.

The operation was performed under endotracheal anesthesia. The first 3 mm trocar was inserted paraumbly. Carbon dioxide was insufflated at a pressure of 3-5 mm Hg. with a flow rate of 1–2 l/min., with stable hemodynamics, then gradually the pressure of carbon dioxide was raised to 7–8 mm Hg. After the introduction of 3 mm optics, an audit of the abdominal cavity was performed. If necessary, additional 3 mm trocars were inserted.

As a rule, during laparoscopic revision of the OBP in stage II-B NEC, there were no signs of intestinal gangrene, but his condition was borderline - there were signs of increasing necrosis; - the intestines are sharply hyperemic in places, there is no peristalsis. Mesenteric vessels in the corresponding areas of progressive NEC gradually thrombose, which aggravates the process. In our case, with limited sections of the intestine subjected to irreversible processes (up to 30–40 cm), through a minilaparotomic incision, under the control of optics, we brought the affected area into the wound and after its resection at the level of healthy tissue, an end-to-end anastomosis was applied. A similar operation for stage II-B NEC was successfully performed in 8 (44.4%) patients, in 6 (33.3%) cases, the affected part of the intestine with the imposition of an intestinal stoma (Figure 1).

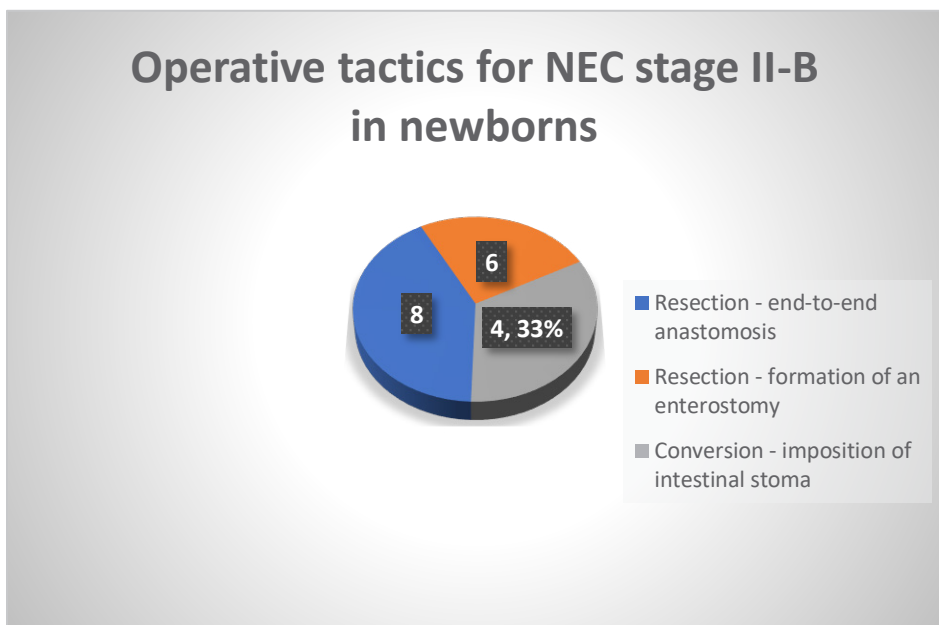


Fig. 1. Operative tactics for NEC stage II-B in newborns.

In the postoperative period, anastomosis failure was observed in 1 (12.5%) case - the patient underwent relaparotomy and a double-barreled enterostomy was applied. In total, among patients operated on in the 2nd stage of NEC, in 2 (11.1%) cases there was a lethal outcome due to the increase in multiple organ failure, which was due to pulmonary edema, cardiovascular, hepatic-renal insufficiency.

Thus, in stage II-B of NEC, a total of 18 diagnostic laparoscopies were performed, which in 14 (77.8%) cases ended with therapeutic laparoscopy, in 4 (22.2%) cases a conversion was performed - laparotomy, resection of the affected part of the intestine with removal of the intestinal stoma (table 1).

Table 1. Results of diagnostic laparoscopies in neonates with stage II-B NEC (N= 18).

Clinical stage of NEC	DL-minilaparotomy - bowel resection end-to-end anastomosis n=8	DL - conversion. Intestinal stoma placement n=4	DL- Intestinal stoma placement n=6	Total N=18
2 -B stage n=14	8*/1	-	6*	14*/1 (12.5%)
2 -B n=4		4/1		4/1
Total	8*/1 (44.4%/12.5%)	4/1 (22.2%/25%)	6* (33.3%)	18/2 (100%/11.1%)

Note sign * - indicates that the operation was performed through a minilaparotomy with video assistance.

The numerator / - indicates the death after surgical interventions.

As can be seen from table 1, mortality in the surgical stage of NEC due to laparoscopic interventions with minilaparotomy and performed operations with video assistance was only 12.5% of cases, which is significantly less than after traditional laparotomies.

It should be noted that for greater objectification of the results of surgical treatment in the compared groups, this is what; We performed DL in children weighing at least 1,500 grams, so such a big difference between mortality rates in the compared groups is not entirely objective and requires further research.

At the same time, the advantages of endovisual interventions are undoubted - a broad overview of the condition of the OBP to determine the tactics and scope of the upcoming surgical intervention, minimization of surgical trauma, practically maintaining the integrity of the anterior abdominal wall (which eliminates complications such as eventration of intestinal loops, the formation of ventral hernias, minimizes infection of the postoperative wound and etc.). Not least important is the reduction in the duration of the operation, which undoubtedly has a positive effect on the outcome of surgical treatment, which, in turn, contributed to the reduction of unwanted complications and mortality.

According to the analysis of operated patients, it turned out that - most often in NEC, the ileum was affected in 11 (61.1%) cases, then the jejunum in 4 (22.2%), in 3 (16.7%) children the large intestine was affected (Table 2).

Table 2. The affected organ in newborns with NEC - stage II-B.

Affected organ	DL - conversion - traditional laparotomy	Laparoscopy - minilaparotomy	Total
Jejunum	1	3	4 (22.2%)
Ileum	-	11	11 (61.1%)
Large intestine	3	-	3 (16.7%)
Total	4 (22.2%)	14 (77.8%)	18 - 100%

In the postoperative period, all children received infusion support, exicosis and electrolyte disturbances were corrected. Enteral feeding was started after 3-5 days, after the child's peristalsis and passage through the intestines were restored, bloating was stopped, there was a strong tendency to improve and normalize laboratory parameters, ultrasound and radiological data. But these terms are absolutely individual for each sick child.

All newborns - 16 (88.9%) children of stage 2B NEC, after surgical treatment and relief of the main symptoms of the disease, were transferred to the neonatal pathology department for further treatment and rehabilitation. The timing of the closure of the intestinal stoma is not possible with strict recommendations in the temporary mode, we believe that this is decided individually in each case, depending on many objective and subjective factors.

Overall mortality among patients with stage II-B NEC was 11.1% (2 out of 18 patients). We believe that in case of exclusion of DL, and operations performed in the traditional way, the mortality rate would be higher.

It should be noted that in a number of cases, mortality was due not only to late diagnosis and surgical complications, but also to intercurrent, concomitant pathologies, developmental anomalies that complicate the course of the underlying disease, causing a fatal increase in multiple organ failure with an unfavorable outcome, regardless of the surgical tactics taken.

4 Conclusions

In stage II-B NEC in newborns, diagnostic laparoscopy, if possible and indicated, should precede radical surgery.

Based on the results of diagnostic laparoscopy, one can imagine further tactics for the upcoming radical surgical treatment.

In stage II-B NEC, in some cases: with non-extended intestinal lesions, diagnostic laparoscopy can be completed with therapeutic laparoscopy itself.

The possibility of transforming diagnostic laparoscopy into therapeutic one minimizes intraoperative trauma, which affects the postoperative survival of patients with stage II-B NEC.

The operation of choice in patients with NEC stage II-B, - (in the case of non-extended necrosis or intestinal damage) is an economical resection of the intestine affected by necrosis with end-to-end anastomosis or the imposition of an intestinal stoma.

References

1. S.A. Karavaeva, *Diagnosis and clinical features of necrotic enterocolitis in children.* Vestnik khirurgii im. I.I. Grekova **(4)**, 41 – 44 (2002)
2. Yu.A. Kozlov, V.A. Novozhilov, K.A. Koal'kov, D.M. Chubko, P.Zh. Baradieva, A.D. Timofeeva, et.al., *Necrotizing enterocolitis in newborns. New views and trends.* Pediatric surgery **20(4)**, 188-193 (2016)

3. R.H. Hashem, Y.A. Mansi, N.S. Almasah, S. Abdelghaffar, *Doppler ultrasound assessment of the splanchnic circulation in preterms with neonatal sepsis at risk for necrotizing enterocolitis*. J. Ultrasound **20(1)**, 59–67 (2017)
4. M. Janssen Lok, et. al., *Value of abdominal ultrasound in management of necrotizing enterocolitis: a systematic review and meta-analysis*. *Pediatr. Surg. Int.* **34(6)**, 589-612 (2018)
5. I.V. Poddubnyy, S.Yu. Kharlamov, T.V. Krasovskaya, N.V. Golodenko, Yu.I. Kucherov, L.A. Romanova, *Conservative treatment of abdominal infiltrate on the background of ulcerative necrotic enterocolitis in newborns*. *Pediatric surgery* **(4)**, 45-47 (1999)
6. T.V. Krasovskaya, V.A. Novozhilov, S.V. Ionushene, E.I. Kikina, *Surgical complications of necrotic enterocolitis in newborns; pathogenetic substantiation of prevention methods*. *Pediatric surgery* **(2)**, 15-19 (2004)
7. A.Yu. Razumovskiy, O.G. Mokrushina, *Endosurgical operations in newborns* (Moscow: OOO «Izdatel'stvo «Meditsinskoe informatsionnoe agentstvo», 2015)
8. V.P. Chevzhik, E.A. Cherpalyuk, *Ulcerative necrotic enterocolitis in multiple pregnancy*. *Pediatric surgery* **(6)**, 52-52 (2004)
9. N.J. Hall, S. Eaton, A. Pierro, *Royal Australasia of Surgeons Guest Lecture. Necrotizing enterocolitis: prevention, treatment, and out come*. *J. Pediatr. Surg.* **48**, 2359-67 (2013)
10. J.C. Chandler, A. Hebra, *Necrotizing enterocolitis in infants with very low birth weight*. *Semin pediatr. surg.* **9(2)**, 63-72 (2000)