

# Histological characteristics of the myocardium of broilers with the use of Nucleostim

Ildar Gatiyatullin<sup>1\*</sup>, George Bazekin<sup>1</sup>, Ilgiz Dolinin<sup>1</sup>, and Evgeniy Skovorodin<sup>1</sup>

<sup>1</sup>Bashkir State Agrarian University, 34, 50-letia Ocyabrya str., Ufa, 450001, Russian Federation

**Abstract.** The article presents the results of research on the use of the biological stimulator Nucleostim in the cultivation of broiler chickens of the ROSS-308 cross. Special attention is paid to the morphological characteristics of the myocardium of broiler chickens, as well as the effect of the biostimulator Nucleostim on the myocardium at the tissue and cellular levels. Histological studies have shown that the biological stimulator Nucleostim optimizes the structure of the myocardium, prevents the development of disorders of cellular metabolic mechanisms in the organ, leading to the development of structural changes.

## 1 Introduction

Currently, poultry farming is one of the largest suppliers of high-grade animal protein. Increasing the production of high-quality livestock products, in particular poultry products, is one of the main tasks of modern science. However, if the technology of keeping and feeding is violated, the state of resistance of the body changes, and the resistance of the bird to diseases decreases. The postnatal period in birds in such conditions is characterized by a state of reduced reactivity of the body, insufficient development of the immunocompetent system in certain age groups. In this regard, there is a need to identify potentially dangerous factors for the health of birds and the expediency of intensive search for pharmacological protection against negative environmental influences that will contribute to the restoration of homeostasis in general, as well as increase productivity and percentage of livestock safety [1-10].

In recent years, broilers have been widely used in poultry farming enterprises in Russia in the production of meat products, but their morphology and age dynamics have not been studied. Cross broilers are the most popular "ROSS 308", allowing you to gain maximum weight and development by 40 days of post-incubation ontogenesis. The heart is one of the most important organs of animals, which is associated with the role of this organ in the process of blood circulation, the movement of blood with nutrients and oxygen, and the regulation of the normal functioning and growth of all organs and the body as a whole. The study of the morphology of the heart allows not only to reveal the question of the peculiarities of age morphology, topography of the development of this organ in domestic birds and animals, but also remains relevant to the present time [3-6, 9].

---

\* Corresponding author: [gatiyatullinildar@yandex.ru](mailto:gatiyatullinildar@yandex.ru)

Recently, increased attention has been paid to the search, development and application of highly effective, safe feed additives and other medicines, which makes it possible to increase their therapeutic effectiveness. At the same time, the use of such drugs often helps to reduce their individual side effects, reduces the dose and, consequently, the cost of treatment.

The disclosure of the patterns of morphofunctional adaptation of the cardiovascular system and the entire body to the effects of hypodynamia with cellular content – physiologically significant stressors and the use of immunomodulating, immunostimulating and antiviral drugs is relevant for the development of sound methods for the prevention of myocardial damage, as well as for the search for the most effective methods to ensure structural stabilization of the cardiovascular system and increase the body's resistance to as a whole. The relevance of the study is determined not only by determining the age-related features of the post-incubation development of the broiler heart, but also by the influence of the new biological stimulator Nucleostim in broiler cultivation [1,2, 7, 8, 11-13].

**The purpose** of this work was to study the effect of the biological preparation "Nucleostim" on the body of broiler chickens of the ROSS 308 cross.

## 2 Materials and methods

In this paper, we have presented descriptions of the material and research methods used for a deeper study of the effect of the biological preparation Nucleostim on the body of broiler chickens. 50 broiler chickens of the ROSS 308 cross were used for the research. The experimental and control groups of animals were kept in the same conditions on a special, balanced diet with free access to water. The work uses: biological stimulator Nucleostim. This drug was introduced into the diet of birds in the right concentrations and given together with the feed according to the instructions for use. The biological material was fixed in a 10% solution of neutral formalin was dehydrated in a series of alcohols of increasing concentration and poured into paraffin according to a generally accepted method. The sections were prepared on a LEICA RM 2145 microtome (Germany), which were stained with hematoxylin and eosin according to Van Gieson.

The live body weight was determined by individually weighing the entire livestock at the age of 5 days, on day 15, on day 25, on day 30. The survival rate of chickens was determined by taking into account the case. The immunobiology of the animal body during intrauterine development is characterized by a number of features. First of all, during this period of ontogenesis, embryonic organs are formed and function – the placenta, yolk sac, allantois and amnion, which perform metabolic and fruit protection functions. Protection of the fetus by temporary embryonic organs consists of maintaining an immunological balance between the fetus and the mother and preventing infection of the fetus. Birds transmit maternal antibodies transovarially. The meager provision of maternal antibodies to the developing organism in itself implies the autosynthesis of antimicrobial factors by fetuses. The antimicrobial activity of natural resistance plays an exceptional role in the life of the body. The microclimate has a great influence on the body of chickens.

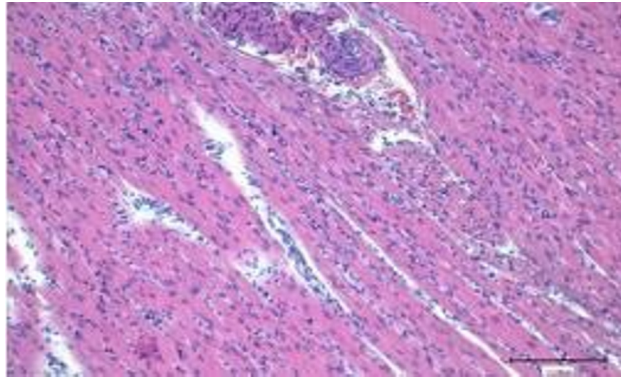
## 3 Results

We tested the Nucleostim when added to feed at a dose of 3 g / kg of feed from the age of 2 days in order to stimulate the growth of chickens and protect them from diseases during cultivation. The chickens were divided into 2 groups. The live weight of 5-day-old chickens of the 1st control group was  $125.7 \pm 4.37$  g, in the 2nd experimental group -  $126.9 \pm 2.80$  g. The first group of chickens in the amount of 10 heads received standard

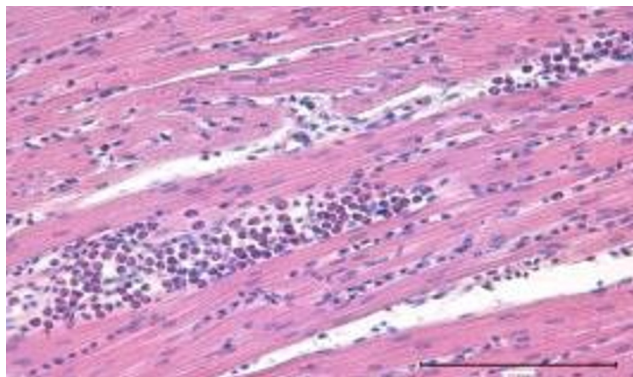
compound feed without additives and served as a control. The second group of 10 heads received standard compound feed with the addition of Nucleostim at a dose of 3 g / kg feed. It can be noted a significant increase in the live weight gain of chickens in the experimental 134 group compared with the control group. After the application of the studied drug (on the 30th day of life), the weight of chickens in group 2 exceeded the weight of chickens in the control group by an average of 27.46%.

During the experiment, all the experimental livestock was preserved, 2 out of 10 chickens fell in the control group, which amounted to 20%. As a result of the introduction of Nucleostim into the diet (3 g / kg of feed), there is an increase in the safety of chickens and an increase in their live weight gain. The studied drug Nucleostim, injected into feed at a dose of 3 g / kg of feed, improves the growth and development of chickens. At the end of the experiment, the average live weight of chickens receiving "Nucleostim" (3 g / kg of feed) increased by 27.46% compared with the control, and also contributes to improving the safety of the studied group.

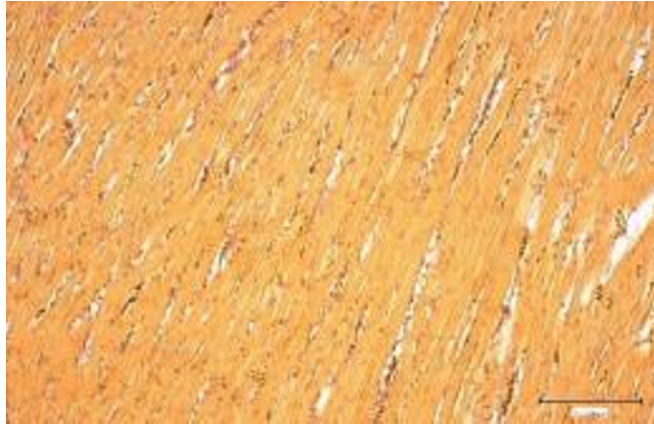
In general, the myocardium of broiler chickens was represented by muscle fibers consisting of cardiomyocytes, which contacted each other through insertion discs characteristic of the myocardium. The cells were arranged in a single-vector order and had a fairly high cell density. The intervertebral spaces and perivascular spaces were somewhat enlarged, probably due to the intrauterine edema. They contained lymphocytes, macrophages, and erythrocytes.



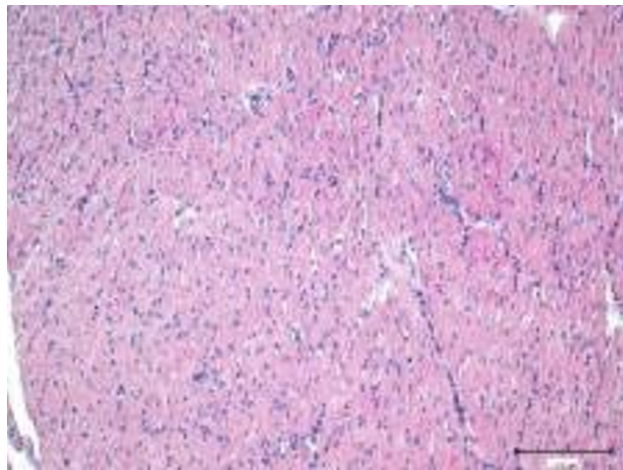
**Fig. 1.** Myocardium of broiler chickens before the use of nucleostim. Intrauterine edema, accumulation of eosinophils. Stained with hematoxylin and eosin.



**Fig. 2.** Myocardium of broiler chickens before the use of nucleostim. Intrauterine edema, clusters of pseudo-eosinophils. Stained with hematoxylin and eosin.



**Fig. 3.** Endomysium in the myocardium of broiler chickens before the application of nucleostome. Painting by van Gieson.



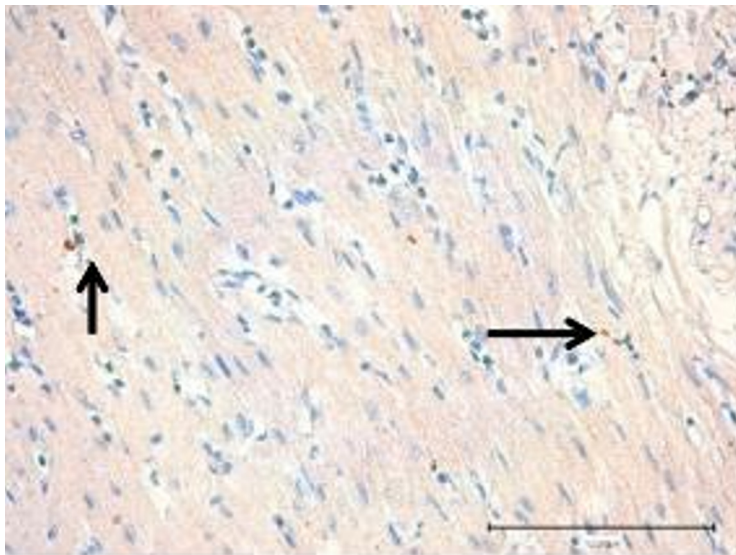
**Fig. 4.** Myocardium of broiler chickens after application of a nucleostim. Staining with hematoxylin and eosin.

Signs of inflammation were found in the myocardium (Figures 1-4). There were extensive accumulations of pseudoeosinophils, hemorrhagic impregnation of fiber-to-fiber interstices with erythrocytes. There were no signs of stasis and sludge of shaped blood elements in the blood vessels. Endomysium in Wangizon staining was found in the form of thin layers of collagen fibers, both between muscle fibers and near blood vessels, mainly the arterial basin. After the application of the nucleostim, during the study, it was found that the infiltration of inflammatory cells was significantly reduced. Single lymphocytes and erythrocytes were detected in interstitial spaces. No clusters of eosinophils were found. No edema phenomena were detected. The muscle cells fit snugly together. The insertion discs were clearly defined between them. The cells retained periodic transverse striation. Thin collagen fibers representing endo - and perimysium of the myocardium without signs of sclerosis were detected between the fibers

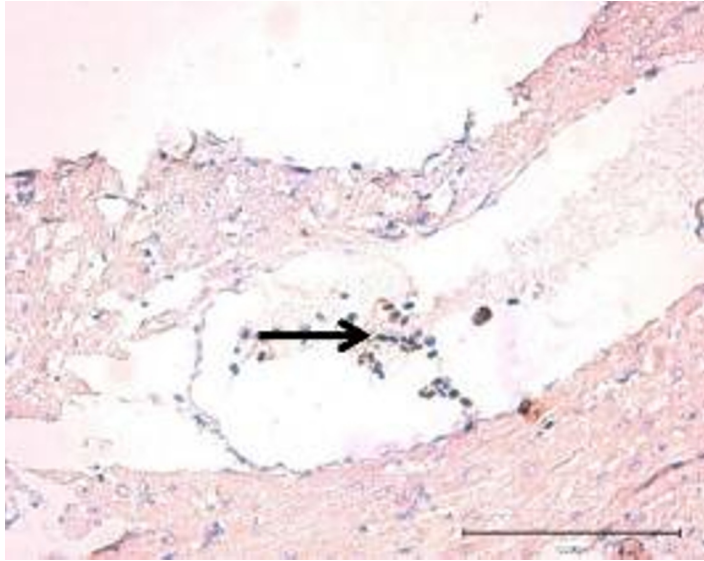
Signs of inflammation were found in the myocardium. There were extensive accumulations of pseudoeosinophils, hemorrhagic impregnation of fiber-to-fiber interstices with erythrocytes. There were no signs of stasis and sludge of shaped blood elements in the

blood vessels. Endomysium in Wangizson staining was found in the form of thin layers of collagen fibers, both between muscle fibers and near blood vessels, mainly the arterial basin. After the application of the nucleostim, during the study, it was found that the infiltration of inflammatory cells was significantly reduced. Single lymphocytes and erythrocytes were detected in interstitial spaces. No clusters of eosinophils were found. No edema phenomena were detected. The muscle cells fit snugly together. The insertion discs were clearly defined between them. The cells retained periodic transverse striation.

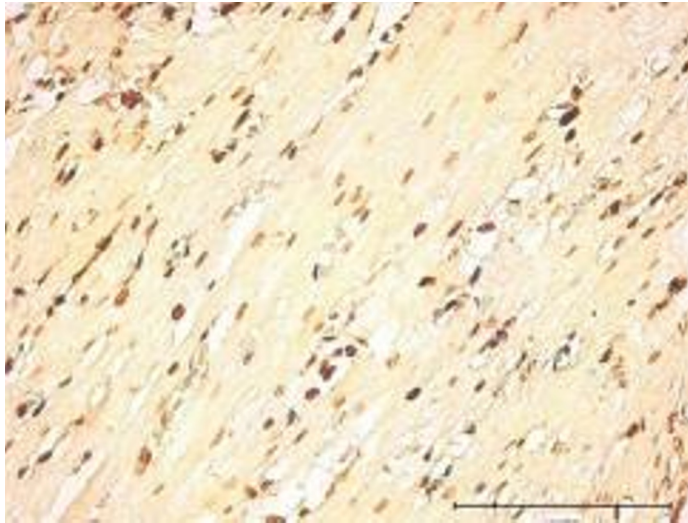
Thin collagen fibers representing endo - and perimysium of the myocardium without signs of sclerosis were detected between the fibers. The blood vessels and perivascular pool were without features. In immunohistochemical detection of Timp-2 + cells in the myocardium of broiler chickens, it was found that in the experimental group the number of positively colored cells was three times higher than the values of the control group. Thus, the median in the control was 2.78 (2-4), in the experiment the median was 6.14 (3-9) cells in the field of view (Figure 5, 6) at  $p \leq 0.05$ .



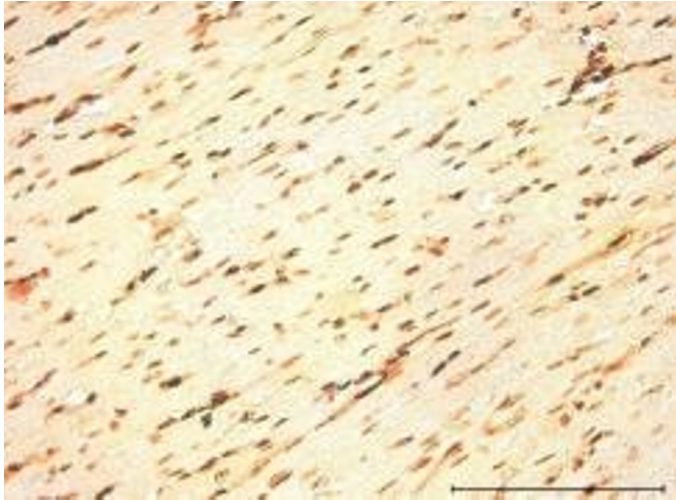
**Fig. 5.** Timp-2 + cells in the myocardium of the experimental group. Immunohistochemical staining with antibodies to Timp-2. Indirect streptavidin-biotin detection system with hematoxylin dye.



**Fig. 6.** Timp-2 + cells in the lumen of a blood vessel. Myocardium of the experimental group. Immunohistochemical staining with antibodies to Timp-2. Indirect streptavidin-biotin detection system with hematoxylin dye.



**Fig. 7.** PCNA+ cells in the myocardium of the control group. Immunohistochemical staining with antibodies to the nuclear antigen of proliferating PCNA cells. Indirect streptavidin-biotin detection system with hematoxylin dye.



**Fig. 8.** PCNA+ cells in the myocardium of the experimental group. Immunohistochemical staining with antibodies to the nuclear antigen of proliferating PCNA cells. Indirect streptavidin-biotin detection system with hematoxylin dye.

The study of proliferatively active nuclei of cardiomyocytes – PCNA, which are often found in dividing cells in young birds with myocardial hypertrophy, revealed quantitative differences between the experimental groups. So, in the control group, the number of dividing nuclei in the myocardium was two times lower than in the experimental group. The median in the control group was 40.28 (34-49), in the experimental group 82 (61- 111) ( $p < 0.05$ ) (Figures 7, 8). Thus, after the application of the nucleostim, signs of a decrease in inflammatory infiltration and the disappearance of edema were revealed. The number of PCNA+ positive cells was doubled, which indicated the activation of intracellular cardiomyogenesis – cardiomyocyte hypertrophy. Stroma cells and cardiomyocytes secreted Timp-2 three times more actively than in the control group, which contributed to cardioprotection initiated by the use of nucleostim.

## 4 Conclusions

The use of the biological stimulator Nucleostim optimizes the structure of the myocardium, prevents the development of disorders of cellular metabolic mechanisms in the organ, leading to the development of structural changes. The research results show that when using Nucleostim, the infiltration of inflammatory cells is significantly reduced, which suggests that the biopreparation helps to reduce the risk of inflammatory processes in the myocardium. It is also seen that the muscle cells are tightly adjacent to each other and maintain a periodic transverse 85 striation, this confirms that the use of nucleostim does not affect the structure of the myocardium of broiler chickens.

In broiler chickens in the experimental group, after using Nucleostim at a dose of 10 g / kg of feed, myocardial infiltration by inflammatory cells was significantly reduced. Single lymphocytes and erythrocytes were detected in interstitial spaces. No accumulations of eosinophils were detected. No edema phenomena were detected. The muscle cells fit snugly together. The insertion discs were clearly defined between them. The cells retained periodic transverse striation.

The study of proliferatively active nuclei of cardiomyocytes-PCNA, which are often found in dividing cells in young birds with myocardial hypertrophy, revealed quantitative differences between the experimental groups. Thus, in broiler chickens in the control group

, the number of dividing nuclei in the myocardium was two times lower than in experienced broilers. The median in the control group was 40.28 (34-49), in the experimental group 82 (61-111) ( $p < 0.05$ ).

Thus, after the use of "Nucleostim" at a dose of 10 g / kg of feed in broiler chickens, signs of a decrease in inflammatory infiltration of the myocardium and the disappearance of edema were revealed. The number of PCNA+ positive cells was doubled, which indicated the activation of intracellular cardiomyogenesis – cardiomyocyte hypertrophy. Stroma cells and cardiomyocytes secreted Timp-2 three times more actively than without the use of Nucleostim in broiler chickens in the control group, which contributed to cardioprotection initiated by the use of Nucleostim.

## References

1. E. V. Vetrova, A. V. Lekar', and N. I. Borisenko, Mass spectrometric analysis of supramolecular complexes of glycyrrhizic acid and simvastatin (Chemistry of natural compounds, Tashkent, 2017)
2. R. N. Wang, Y. Y. Liu, J. Chen, H. L. Wang, and J. S. Li, Antitumor mechanism of glycyrrhizic acid and glycyrrhetic acid and their application as drug delivery carriers (Chinese traditional and herbal drugs, China, 2019)
3. G. Bazekin, E. Skovorodin, I. Dolinin, I. Gatiyatullin, I. Chudov, and A. Ezhkova, The effect of new immunostimulants of tissue and plant origin on the morphological characteristics of the immune system's central organs and the dynamics of serum immunoglobulins (Advances in Animal and Veterinary Sciences, Pakistan, 2021)
4. G. V. Bazekin, I. R. Gatiyatullin, E. N. Skovorodin, A. R. Sharipov, and I. R. Dolinin, Stimulating cellular and humoral natural resistance factors in calves with bronchopneumonia using glycyrrhizic acid (Advances in animal and veterinary sciences, Pakistan, 2021)
5. L. A. Baltina, A. I. Fairushina, M. Y. Eropkin, N. I. Konovalova, P. A. Petrova, E. M. Eropkina, Synthesis and antiviral activity of glycyrrhizic-acid conjugates with aromatic amino acids (Chemistry of natural compounds, Tashkent, 2017)
6. M. Bulegenova, K. Biyashev, Z. Kirkimbaeva, B. Biyashev, S. Ermagambetova, K. Oryntayev and A. Altenov, The effect of the drug "Enterocol" on the humoral factors of calf body resistance (Advances in Animal and Veterinary Sciences, Pakistan, 2019)
7. O. V. Smolovskaya, T. V. Zubova, and L. N. Korobeinikova, Experience of fir tree extract application for prevention of gastrointestinal tract diseases in newborn calves (prevention of calf dispepsy (Annals of agri bioresearch, India, 2022)
8. R. K. Gadzaonov, R. S. Omarov, B. A. Dzagurov, A. T. Zaseev, and B. S. Nikkolova, Therapeutic and prophylactic use of a complex of biologically active substances and probiotics in the gastrointestinal diseases of newborn calves, Research journal of pharmaceutical, biological and chemical sciences, India, 1521-1527 (2018)
9. M.D. Dabeva, D.A. Shafritz, Liver. Dis. **23(4)**, 349–362 (2003)
10. D. Mc Cormick, P. A. Hall, Histopathology **21**, 591-543 (1992)
11. T. Ito, Effects of antiglaucoma drops on MMP and TIMP balance in conjunctival and subconjunctival tissue. Invest Opth **7(1)**, 71–79 (2005)
12. W. U. Kim, S. Y. Min, M. L. Cho, et al., Res Ther. **7(1)**, 71–79 (2005)
13. E. Skovorodin, G. Bronnikova, G. Bazekin, et al., Veterinary World **12(1)**, 1716- 1728 (2019)